

Congenital talipes equinovarus

■ Incidence 1 in 1000 each live births

Theories of pathogenesis

■ Extrinsic theory

- Postural causes
- Oligohydramnios

■ Intrinsic theory

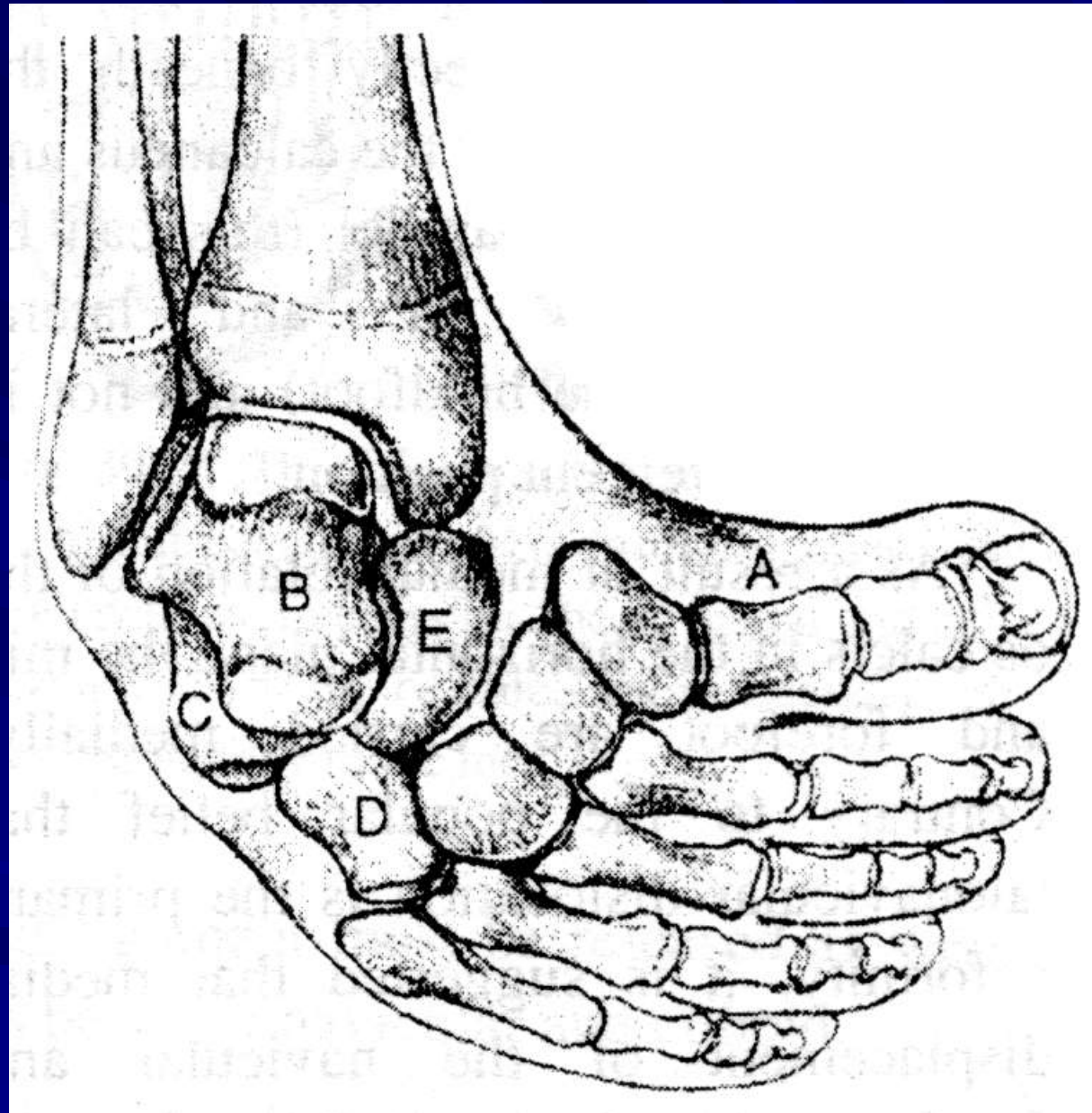
- Germ plasm defect
- Developmental arrest theory
- Neurogenic theory
- Retraction fibrosis
- Anomalous tendinous insertion

Pathological anatomy

- Adduction and supination of forefoot
- Inversion of heel and subtalar joint
- Equinus ... ankle
- Cavus
- Internal tibial torsion

Pathological changes

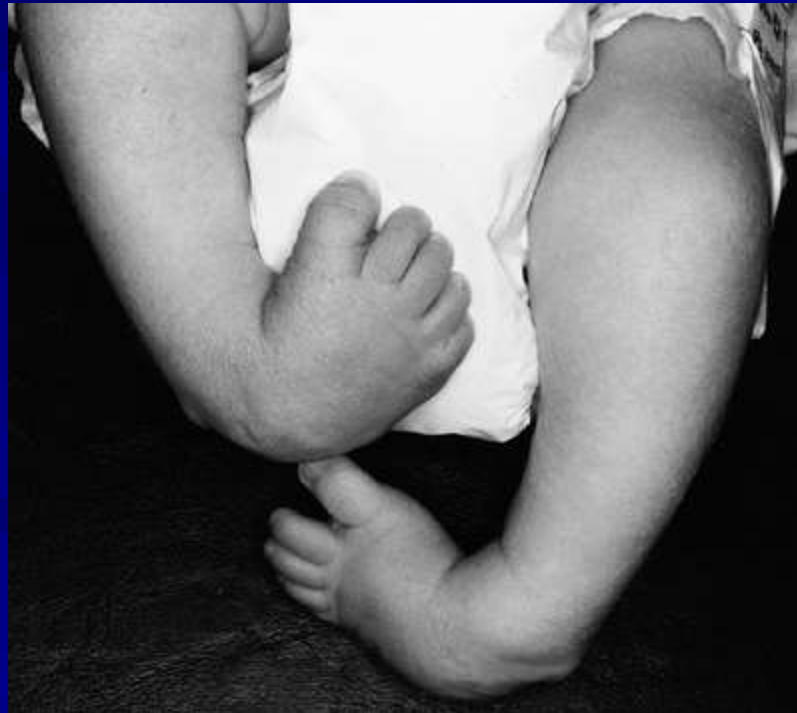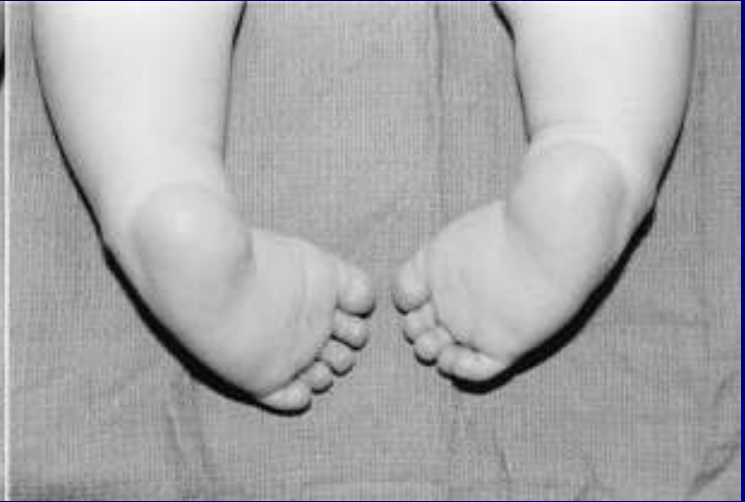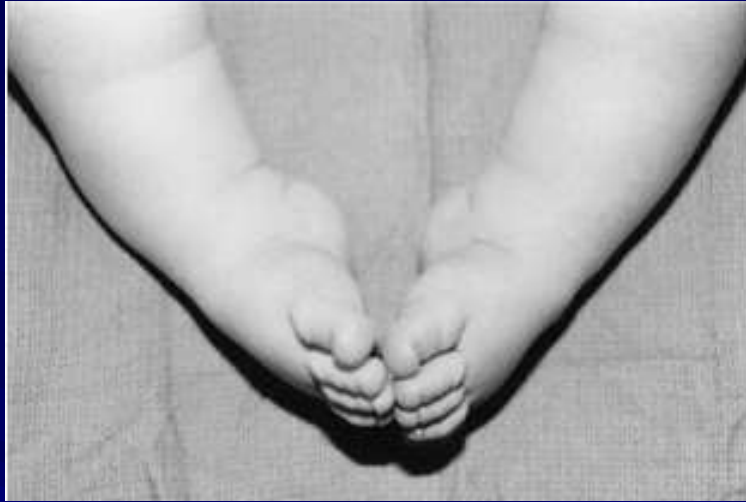
- Contractures of triceps surae, tibialis posterior, FHL, FDL, posterior capsule and collateral lig. Of ankle
- Talus is in equinus, with medial and plantar deviation of the neck and external rotation of the body in the mortise
- Calcaneus in equinus and medial rotation
- Navicular is subluxated medially on talus



Clinical assessment

■ General examination

- Other congenital anomalies ... cleft palate, cardiac anomalies, congenital dislocation hip
- Other etiologies for talipes equinovarus
 - Neuropathic ... polio, C.P., Meningocele, Lateral popliteal nerve palsy
 - Osteopathic ... tibial hemimelia, congenital deficiency of medial ray of the foot
 - Myopathic ... arthrogryposis multiplex congenita



Severity of club foot

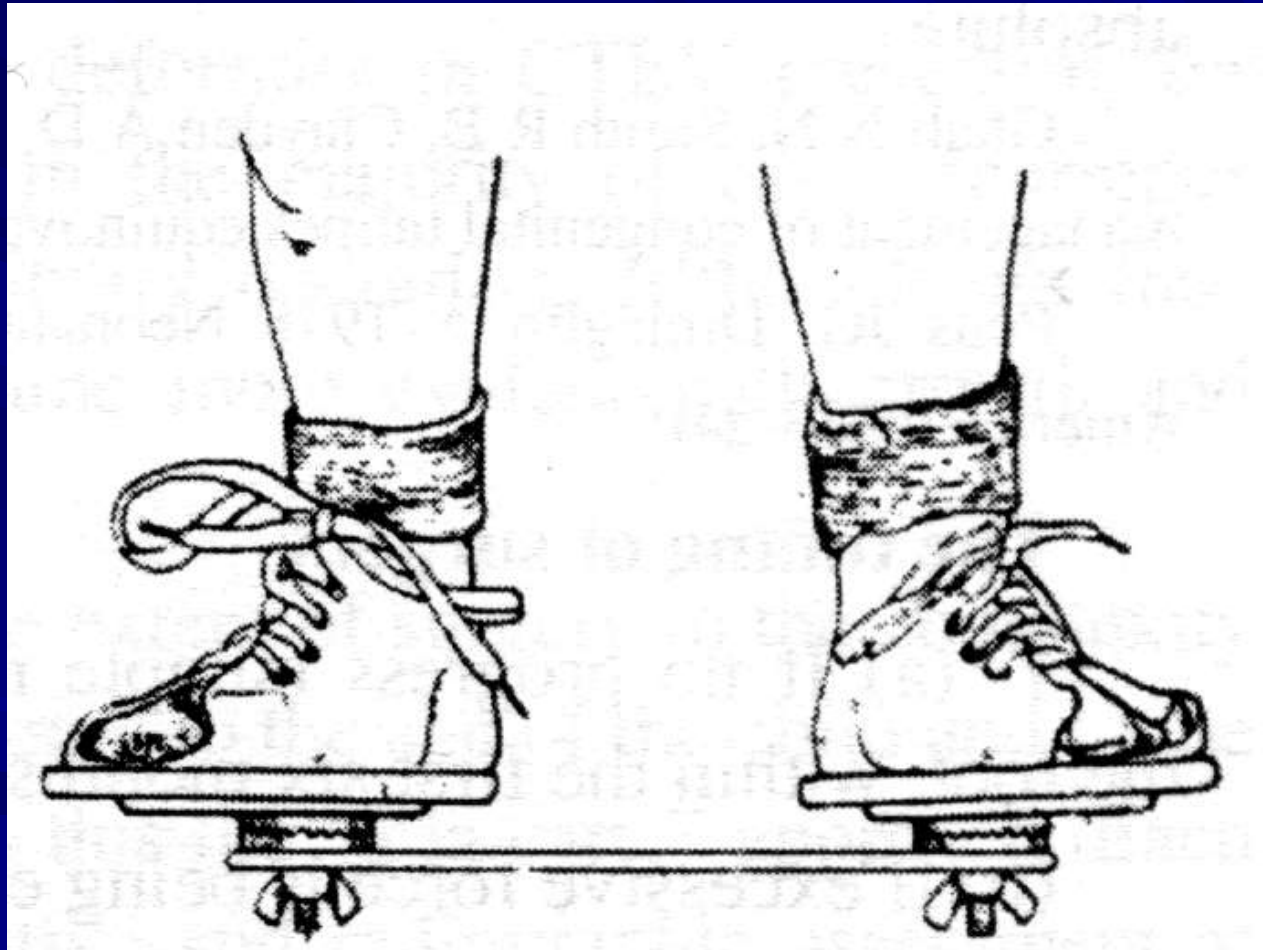
- Calf atrophy
- Small sized heel
- Skin creases

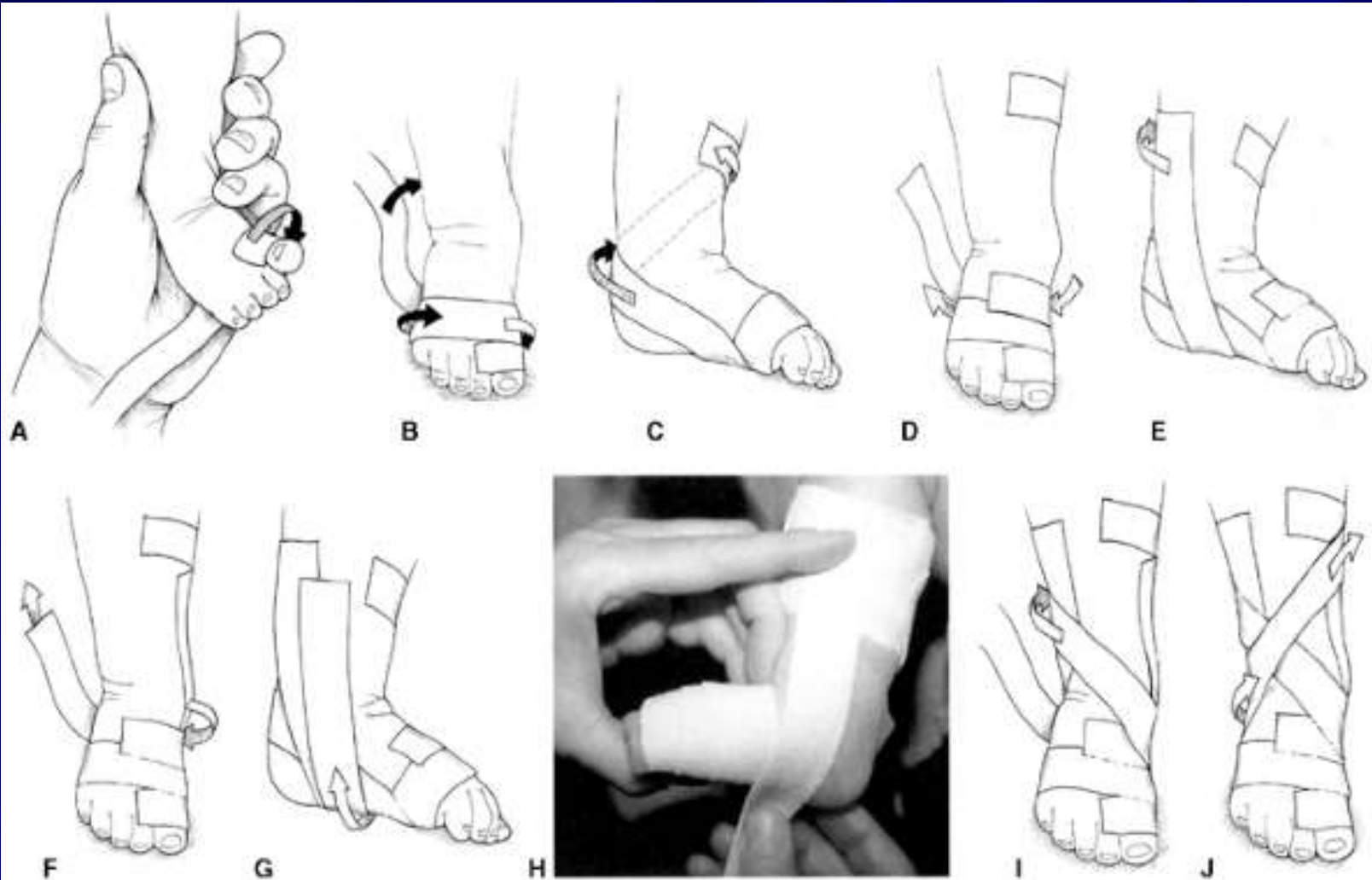
Dimeglio (1994) - categories of CTEV

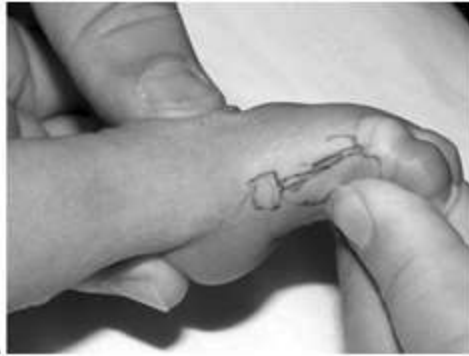- Stiff (irreducible)
- Severe (slightly reducible)
- Mild (partially reducible)
- Postural (totally reducible)

Non-operative treatment

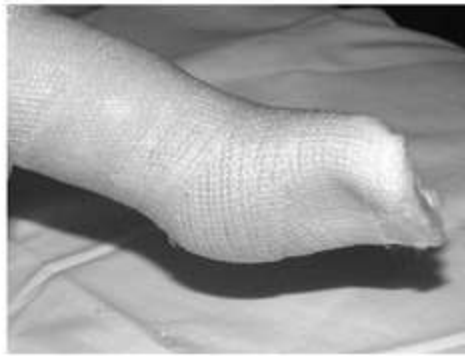- Adhesive strapping
- Denis-Brown splints
- Manipulation and cast



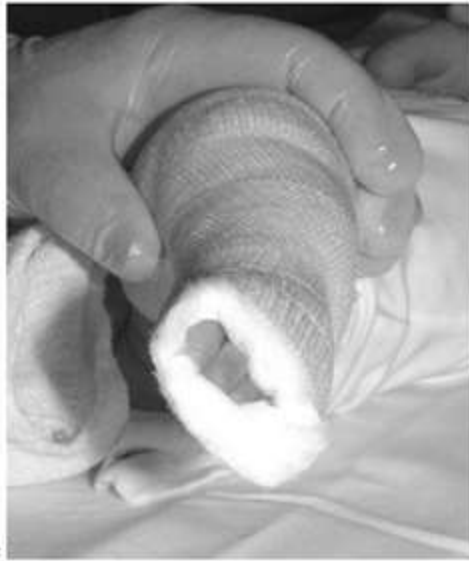



A



B



C

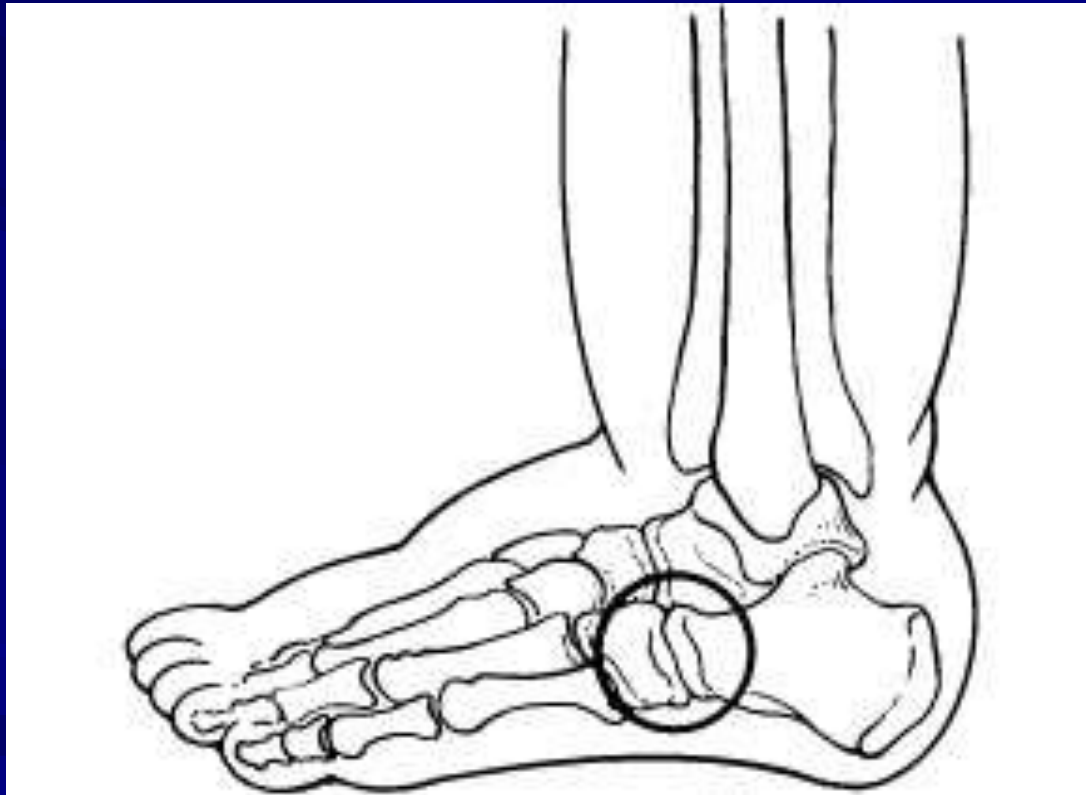
Principles of treatment of CTEV

- Early correction
- Gentle correction
- Overcorrection
- Maintenance
- Supervision

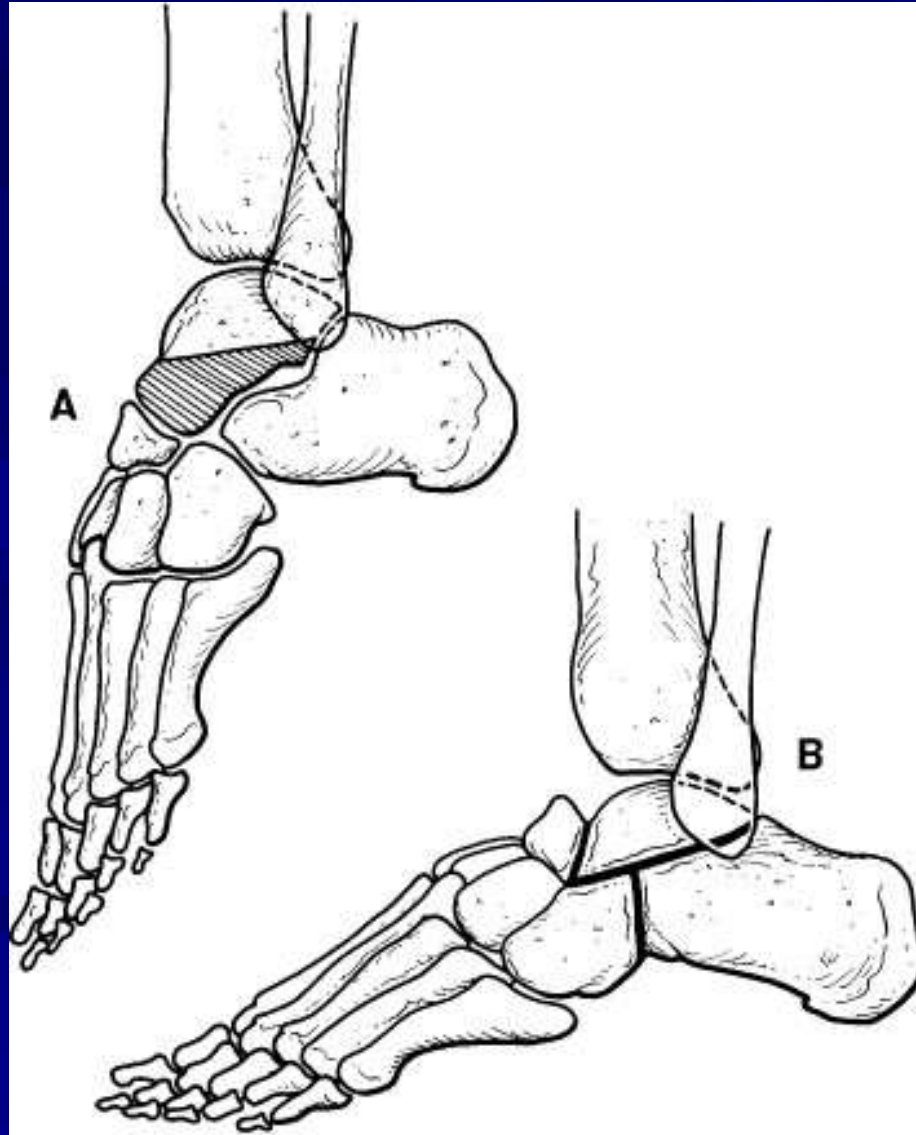
Operative management

- Soft tissue release
 - posteromedial release ... release of all posterior and medial soft tissue structures
 - Tendocalcaneus
 - Tibialis posterior
 - Flexor digitorum longus
 - Flexor hallucis longus
 - Capsule of ankle, subtalar, talonavicular, naviculocuneiform joints
- Combined soft tissue and bony procedures
 - Evan's procedure
 - Posteromedial soft tissue release
 - Calcaneocuboid fusion
- Tendon transfer ... tibialis anterior split
- Bony procedures
 - Lambrinudi procedure
 - Triple arthrodesis
- Ilizarov technique

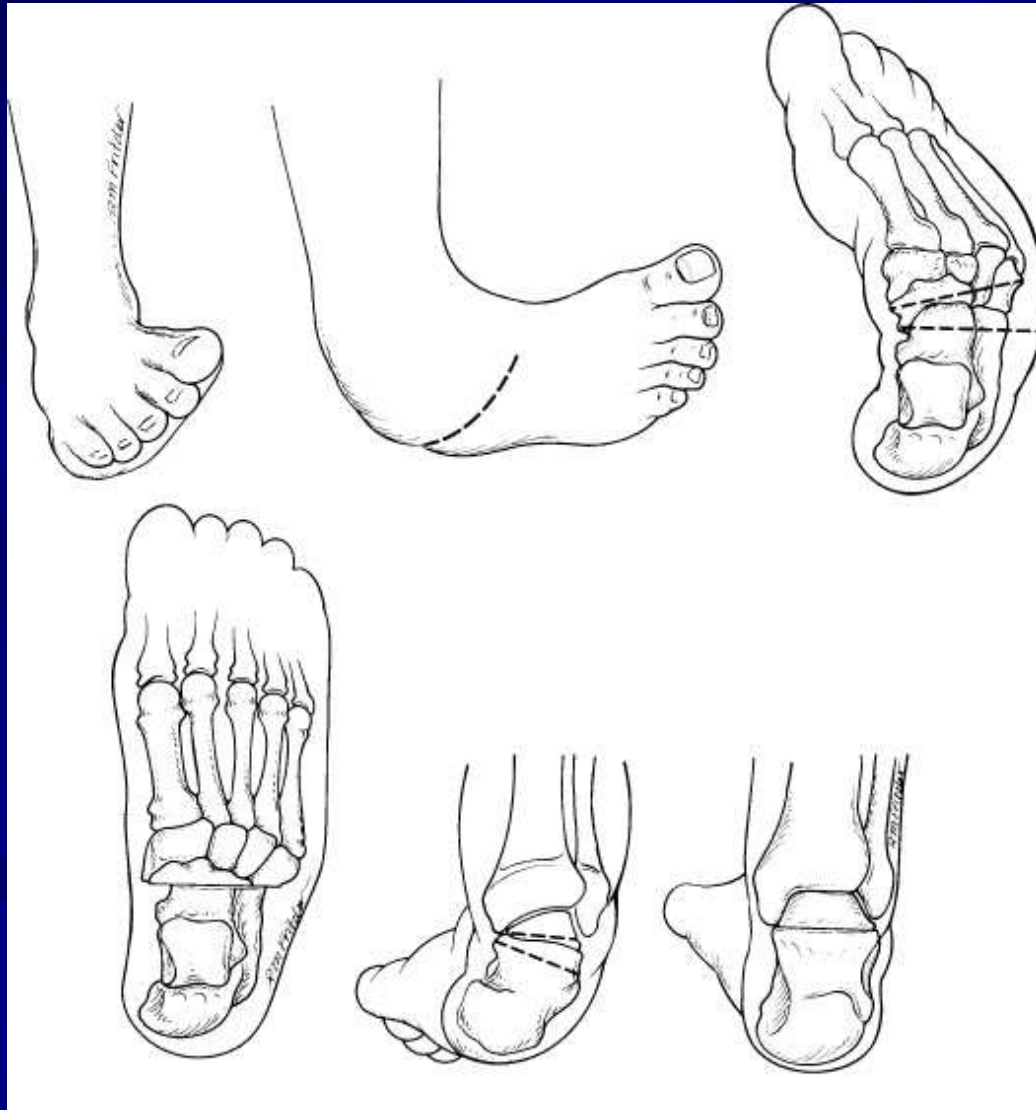
Evan's procedure



Lambrinudi procedure



Triple arthrodesis



Ilizarov technique

